Efficacy of Ferumoxytol (Feraheme) as a Lymphatic Contrast Agent in Prostate Cancer

ASCO 2018 Genitourinary Cancer Symposium

February 8-10, 2018

Purpose:

To determine whether Feraheme has diagnostic utility

Background

There are about 180,000 newly diagnosed cases of prostate carcinoma in the United States each year, with 26,000 deaths per year. Due to the marked variability and aggressiveness of this cancer, evaluation for both osseous and lymphatic metastatic disease is important to determine prognostic implications.

Fereheme Background

Ultrasmall superparamagnetic iron oxide (USPIO) nanoparticle coated with a low molecular weight semi-synthetic carbohydrate.
Intravenously (IV) administered and marketed for treatment of anemia in adult patients
Lymphotrophic agent absorbed by macrophages in the lymph nodes and reticuloendothelial system.

Normal Lymph Node Suppression with MRI

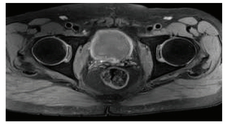

Post contrast T1 demonstrates heterogeneous enhancement of bilateral femoral lymph nodes.

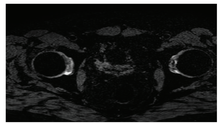

T2* sequence after Feraheme administration. There is complete and homogeneous suppression of signal corresponding to normal uptake of Feraheme by the lymph nodes.

Abnormal Lymph Node

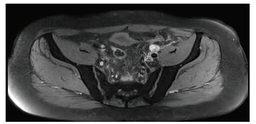

Demonstrates a homogeneously enhancing left external iliac lymph node

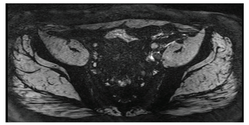

Demonstrates a T2* sequence post Feraheme lymph node with abnormal hyperintense signal.

Methods

- Non-randomized prospective
- 178 consecutive patients (2/13 – 3/15)
  - High risk for lymph node dissemination
  - Analyses of only those with positive findings on MRI
  - All received Feraheme
    - 177 at 6 mg/kg
    - 1 with 3 mg/kg
- All patients underwent MRI with MEDIC/T2* sequencing 24 hours after infusion.
- Images were independently reviewed by two board certified diagnostic radiologist with consensus interpretation
- Readers were blinded to clinical and histopathology

Methods

- Group 1 (94 patients): Abnormal lymph nodes if no suppression after Feraheme infusion (i.e., hyperintense on T2*/MEDIC sequence)
  - 83 (86%) had CT guided biopsies and 11 (14%) an open PLND
- Group 2 (85 patients): Suspicious lymph nodes by MRI if suppressed by Feraheme but with high intensity on DWI, decreased ADC map values, typical morphologic and/or size criteria
  - 76 (89%) had CT guided biopsy and 9 (11%) an open PLND
- Resected lymph nodes were stained and reviewed by a single pathologist with no knowledge of the MRI findings
- The histopathology results for each lymph node were catalogued for comparison with MRI findings

Results

- Group 1
  - 90 (96%) had metastatic prostate cancer
  - 4 (%) were normal
  - 68 (76%) of Group 1 patients had malignant nodes not fulfilling the usual MRI criteria (lower limits of resolution 2-3 mm)
  - Sensitivity 70%
  - Specificity 92%
  - Positive Predictive Value 96%
  - Negative Predictive Value 54%
  - Accuracy 76%

Results

- Group 2
  - 39 (46%) had metastatic prostate cancer
  - 46 (54%) were normal
- Overall combining Groups 1 and 2
  - Sensitivity < 100%
  - Specificity ~ 92%
- One group 2 patient had a mild allergic re action resulting in hives

Conclusion

- With MEDIC/T2* sequences, lack of suppression of signal in lymph nodes after infusion of Feraheme highly suggests lymphatic dissemination in prostate cancer patients. Our findings suggest a lower limit of resolution of 2-3 mm.
- Combining Feraheme Imaging with additional MRI sequences improves sensitivity and specificity.
- Toxicity was acceptable at 6 mg/kg

Table 1

Adverse Events and Administration Technique

A. Aggregate Adverse Events Reported in Postmarketing Safety Trials[a]

Event type	n (total n = 10425)	Total percent	Percent range
Gastrointestinal	174	1.74%	0.6–12.3%
Headache	57	4.21%	1.8–13.3%
Muscle spasm/arthralgias	40	2.96%	1.7–23.3%
Cough/sneezing	21	0.22%	0.1–5%
Pruritis/rash/flushing	68	0.68%	0.4–10%
Dizziness	56	0.56%	0.2–5%
Dyspnea/chest pain	48	0.48%	0.2–5%
Hypersensitivity	12	0.14%	0.1–0.1%
Hypotension	31	0.55%	0.4–2.5%
Peripheral edema	25	3.36%	2.5–3.5%
Anaphylaxis	3	0.03%	0.02–1.3%
CCAEE	9	0.89%	0.8–1%
Urinary tract infections, nasopharyngitis	39	5.67%	5.4–7.5%

B. Ferumoxytol Administration Technique at Rates Concordant with FDA Recommendations; Some Applications May Benefit from Bolus Infusion[b]

Parameter	Recommendation	K-complex
Indications	Vascular imaging, oncology (pediatrics, nodal metastasis)	Vascular imaging as renal insufficiency
Premedication	30 mg elemental iron iv.;	
Full therapeutic dose	18.6 mg/kg (over 7.5 mg/kg doses over 3–6 day period)	For 70 kg adult, full dose is 1570 mg (two vials, one vial given as a time separated by a few days)
MRI dose	1–7.5 mg/kg	Example 1: 3 mg/kg dose in a 70 kg child: 210 mg = 2 mL 10 mg = 60 mg (given 30 mg iv.), leaving remainder, 2 mL (dose)
Dilution	1 part undiluted ferumoxytol in 3–4 parts normal saline (ie. no concentration of ml higher than 10 mg/mL);	Example 2: 3 mg/kg dose in a 70 kg child: 60 mg = 2 mL ferumoxytol in 6 mL saline for a total of 8 mL
Infusion rate	Up to 0.5 mg/s	1 mL/min = 0.5 mg/s; 2 mL/min = 1 mg/s; 4 mL/min = 2 mg/s; 8 mL 70 mg = 250 kg = 10 mL ferumoxytol in 170 mL saline for a total of 70 mL
Rapid bolus	Up to 2 mL/s (saline dilution); NB: Not presently recommended by FDA	
Monitoring	Blood pressure, heart rate, and oxygen saturation before, 5 min after, and 1 hour after administration	
Personnel	Physician with cardiorespiratory management training and ACLS and/or PALS certification as department; licensed nurse or physician as primary in emerging room	

[a]Bristol et al (n = 404), Vedhan-Rai et al (n = 600), MacDougall et al (n = 89), Schiller et al (n = 8860), Auschach et al (n = 10), Lu et al (n = 603) (N)

Note: Although bolus infusion has been reported in revised imaging publications, the FDA labeling for ferumoxytol advises against bolus infusion.

Normal Lymph Node Suppression with MRI

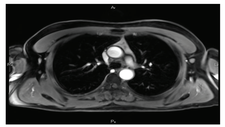

Post contrast T1 weighted image demonstrates enhancement of the left axillary lymph node.

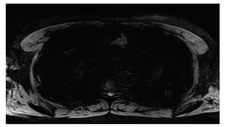

Demonstrates complete and homogeneous suppression of the lymph node on T2* sequencing after Feraheme administration. This corresponds to normal uptake of the Feraheme by the lymph node.